

CASE REPORT

PEER REVIEWED | OPEN ACCESS

Rickets secondary to cystinosis-induced renal Fanconi syndrome: A case report

Maryam Khan, Patricia Beach, Sarah Hussein,
Mariam Jabr, Jarir Halazun, Hani Serag

ABSTRACT

Introduction: Fanconi syndrome consists of proximal tubular dysfunction, causing generalized renal wasting that results in loss of nutrients. In the pediatric population it commonly presents with polyuria, polydipsia, and growth failure due to rickets. Rickets is inadequate bone mineralization at the growth plate, which can be due to a deficiency in either calcium, phosphate, or vitamin D.

Case Report: A 17-month-old male from Anbar, Iraq presented to Jordan Hospital in Amman, Jordan for an opinion regarding diagnosis and management of rickets secondary to nephropathic cystinosis (NC). Prior to evaluation at Jordan Hospital, the patient underwent extensive evaluation and treatment in Iraq starting at age of 12 months. Rickets was an incidental finding on radiographs obtained at that time in an evaluation of fever, and the resulting evaluation spanned five months due to challenges encountered in a low-resource setting. Initiation of appropriate treatment has improved his overall health.

Conclusion: The most common cause of rickets, particularly in societies impacted by war and social unrest, is nutritional. This case highlights the importance of considering other etiologies. We discuss the common clinical features of Fanconi syndrome secondary to NC, while also highlighting the many obstacles faced by the patient in receiving an accurate diagnosis, which is essential to the provision of appropriate interventions.

Keywords: Global health, Nephropathic cystinosis, Pediatrics, Rickets

How to cite this article

Khan M, Beach P, Hussein S, Jabr M, Halazun J, Serag H. Rickets secondary to cystinosis-induced renal Fanconi syndrome: A case report. *J Case Rep Images Pediatr* 2020;2:100009Z19MK2020.

Article ID: 100009Z19MK2020

doi: 10.5348/100009Z19MK2020CR

Maryam Khan¹, Patricia Beach², Sarah Hussein¹, Mariam Jabr³, Jarir Halazun⁴, Hani Serag⁵

Affiliations: ¹MD Candidate, School of Medicine, University of Texas Medical Branch (UTMB), Galveston, Texas, United States of America; ²MD, Professor, Department of Pediatrics, University of Texas Medical Branch (UTMB), Galveston, Texas, United States of America; ³MD, Department of Pediatrics, Jordan Hospital, Amman, Jordan; ⁴MD, FAAP, Chairperson, Department of Pediatrics, Jordan Hospital, Amman, Jordan; ⁵MPH, Director of Programs and Adjunct Assistant Professor, Center for Global and Community Health and Department of Pediatrics, University of Texas Medical Branch (UTMB), Galveston, Texas, United States of America.

Corresponding Author: Hani Serag, MD, MPH, The University of Texas Medical Branch (UTMB), 301 University Blvd., Galveston, Texas 77555-0920, United States of America; Email: haserag@utmb.edu

Received: 29 September 2020

Accepted: 03 November 2020

Published: 04 December 2020

INTRODUCTION

Rickets is a pediatric bone disease that results from inadequate mineralization of the osteoid matrix at the growth plate. It can present with osteomalacia, which is impaired mineralization of the bone matrix [1]. Despite advancements in preventive medicine, rickets continues to contribute to global disease burden and is associated with significant pediatric morbidity and mortality [2]. Currently, the greatest disease burden is in countries from the Middle East, Asia, and Africa with a prevalence ranging between 10% and 70% [1]. This wide range in prevalence is due to variations in diagnostic criteria between countries along with differences in documentation and reporting of total cases [1, 2].

Ineffective mineralization in osteomalacia and rickets is due to nutritional deficiencies in vitamin D or calcium,

or decreased availability of phosphate [1, 2]. Regardless of the deficient mineral, resulting clinical manifestations are similar [1]. The clinical signs and symptoms primarily pertain to musculoskeletal findings including parietal and frontal bossing, widening of the wrist, lateral bowing of the femur and tibia, and delayed fontanelle closure [1, 2]. Though rickets is often due to malnutrition, genetic conditions and renal pathology may be the underlying cause. Renal Fanconi syndrome (RFS) is one of many etiologies that can result in rickets. It is characterized by dysfunction of the proximal tubule, resulting in generalized renal wasting of many nutrients, including calcium and phosphate. It occurs in many genetic disorders. One such disorder is cystinosis [3].

There are three phenotypic presentations of cystinosis: NC, intermediate cystinosis, and non-nephropathic (ocular) cystinosis [4]. Of these three conditions, NC has a prevalence of about 1 out of 100,000 to 200,00 live births in developing nations [5]. It is an autosomal recessive lysosomal storage disorder that results in toxic accumulation of cystine within many organs. Clinical manifestations include RFS, delayed growth, hypophosphatemic and hypocalcemic rickets, and widespread organ dysfunction due to cystine accumulation in cells [5]. We present a pediatric case that details the effects of chronic untreated NC. Appropriate and effective treatment of rickets requires investigating the underlying etiology. Given the prevalence of this genetic disorder and the associated sequelae, NC should be considered on the differential diagnosis when assessing a case of rickets.

CASE REPORT

A 17-month-old male from Anbar, Iraq was admitted to the pediatric unit in Jordan Hospital (JH) in Amman, Jordan. Prior to being admitted, he had an extensive clinical journey that spanned 5 months, which initially began at 12 months when he was admitted to Central Pediatric Hospital in Baghdad for tonsillitis. During this admission, an X-ray showed fraying and cupping of the left ulnar head. Prior to being discharged, he was diagnosed with osteopenia. At 14 months, he was readmitted for a second episode of tonsillitis, which resolved with treatment. At 15 months, the patient was seen at a clinic in Fallujah, Iraq for polyuria and polydipsia. It was characterized as “drinking water to the point of vomiting” along with frequent wet diapers, occurring every 2 hours. At this time, labs exhibited hypokalemia and metabolic acidosis. At 16 months, a more detailed workup was done at Welfare Child Hospital Bab Al-Moatham in Baghdad. Slit lamp examination showed cystine corneal deposition, urine analysis showed phosphaturia and serum cystine levels were elevated. During this visit he was diagnosed with both rickets and NC and was subsequently prescribed oral cysteamine pills and vitamin D supplementation.

Upon admission to JH, the primary complaints included persistent polydipsia, polyuria, and poor appetite. Despite having received the final diagnosis of NC in Iraq, his parents had traveled to Jordan for the sole purpose of reconfirming the diagnosis. Vitals upon admission were temperature of 36°C, pulse of 85 beats per minute, respiration rate of 25 per minute, and blood pressure of 101/65 (90–95%). His weight was at 3rd–5th percentile, height <3rd percentile, and head circumference was at the 90th percentile. Physical exam findings included frontal bossing, poor dentition, rachitic rosary (Figure 1), opened anterior fontanelle and lateral tibial bowing (Figure 2). An X-ray of the left and right forearm also exhibited fraying and cupping of the ulnar head (Figure 3A and B). Developmental history was most notable for language regression; the patient stopped speaking at 14 months. Family history was significant for three paternal cousins, all of whom were siblings, who died secondary to an unspecified kidney disease. The patient’s parents were also consanguineous.

Lab findings were significant for hypochloremic metabolic acidosis, hypocalcemia, hypophosphatemia, and hypovitaminosis D. Furthermore, urine analysis exhibited increased excretion of electrolytes, amino acids, glucose, and protein. No cystine crystal corneal deposition was noted on slit lamp examination. Though the patient had received a prior diagnosis of NC in Baghdad, an attempt to remeasure serum cystine levels was made. However, due to faulty equipment, this could not be completed. Treatment was aimed at replenishing lost nutrients, along with initiating treatment of underlying NC, which included: alfacalcidol, potassium gluconate, sodium bicarbonate, sodium chloride, and cysteamine. After clinical reconfirmation and prescription of a treatment regimen, the patient and his family returned to Anbar, Iraq.

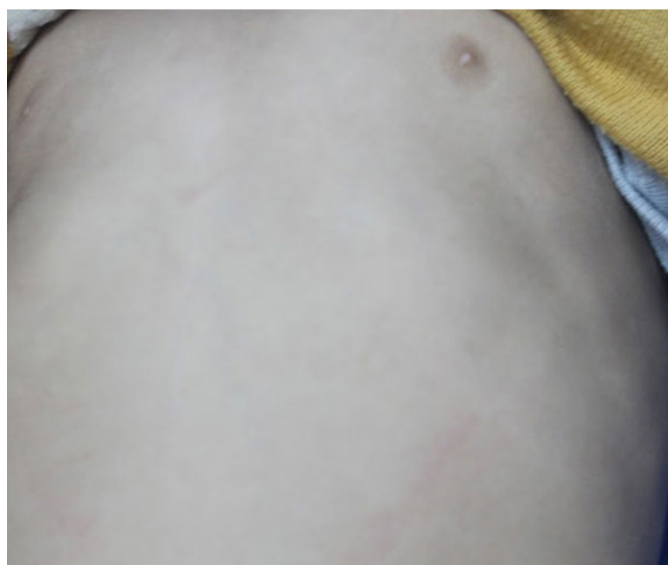

Figure 1: Rachitic rosary at the left costochondral junction.

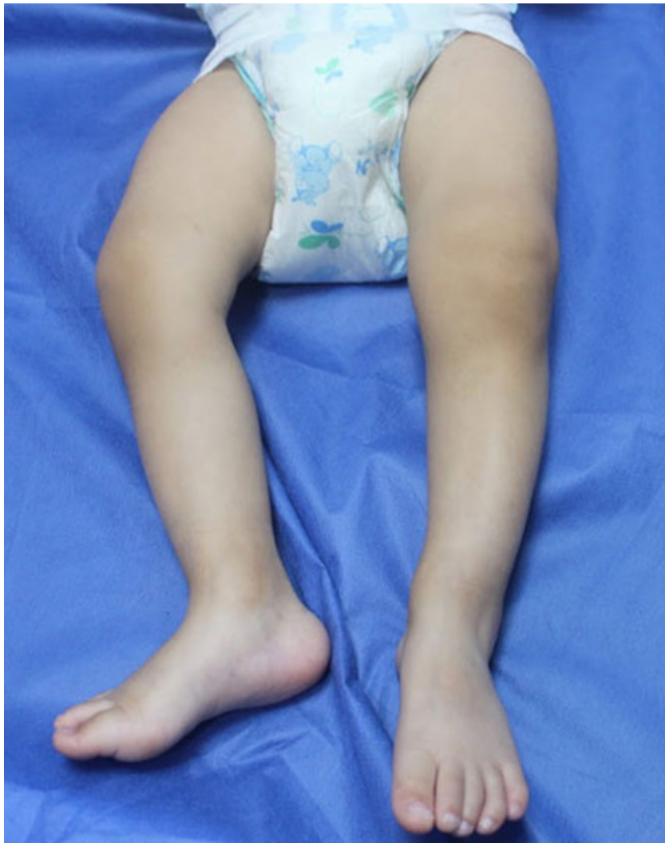

Figure 2: Left lateral tibial bowing.

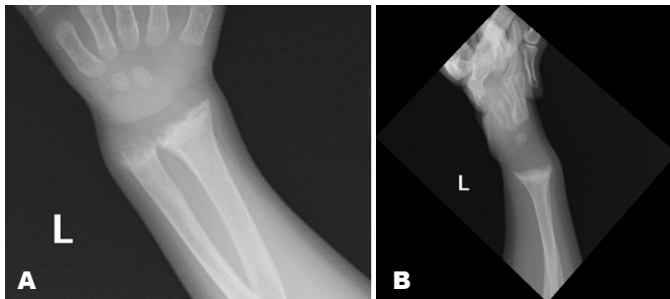


Figure 3: X-ray of left upper extremity. (A) Frontal view of left epiphyseal plate. (B) Lateral view of left epiphyseal plate and ulnar head.

DISCUSSION

Rickets is often attributed to nutritional deficiency of vitamin D or calcium. Though most cases in developing countries are secondary to malnutrition, it is necessary to rule out organic causes, including RFS. Persistent renal wasting of phosphate or calcium, even with adequate mineral supplementation will not improve a patient's condition. Resulting chronic deficiencies can result in physical manifestations of rickets, language regression, and overall failure to thrive [3].

Renal Fanconi syndrome may be due to an underlying genetic condition and/or multiorgan disorder [3].

Nephropathic cystinosis, also referred to as infantile cystinosis, is the most common cause of RFS in children. Due to its prevalence, it is the initial genetic condition that is considered when assessing the etiology of RFS. Failure to thrive initially begins around 6–9 months of age, and by 18 months of age symptoms of polyuria, polydipsia, and rickets are seen [6]. Definitive diagnosis of NC requires one of the following: corneal cystine crystal deposition on slit lamp examination by 12 months of age, elevated cystine concentration in polymorphonuclear leukocytes, biallelic pathogenic mutations in CTNS gene, and elevated cystine in cultured fibroblasts or placenta at birth [4].

Though NC could not be definitively confirmed during the patient's admission at Jordan Hospital, he exhibited the clinical, laboratory, and radiographic findings associated with NC, which included failure to thrive, reduced appetite, polyuria, polydipsia, rachitic skeletal changes, hyperchloremic metabolic acidosis, RFS, and radiography suggestive of rickets. Furthermore, his parent's consanguinity and family medical history of unspecified kidney disease in multiple paternal cousins suggested a genetic etiology for his condition. Mainstay treatment includes replenishing lost nutrients and cysteamine which prevents intracellular accumulation of cystine.

Prognosis of NC is dependent on timely diagnosis and early initiation of treatment. Despite treatment with cysteamine, many patients develop further complications due to widespread cystine deposition in tissue. Long-term sequelae include renal failure, hypothyroidism, myopathy, retinopathy, pulmonary insufficiency, and hypergonadotropic hypogonadism [7]. However, patients who received continuous treatment for at least eight years have shown significant reduction in overall morbidity and mortality [7]. In our presented case, the patient's lengthy clinical journey exhibited the detrimental sequelae associated with delayed diagnosis. Most notably, the initial incorrect diagnosis of osteopenia rather than rickets at 12 months in Baghdad contributed to the overall delay in prompt assessment and diagnosis. An earlier diagnosis of rickets might have resulted in earlier recognition of RFS and NC. The World Health Organization statement on rickets notes that, one of the primary obstacles in adequate and prompt diagnosis of rickets is the lack of consensus on diagnostic criteria, prevention, and treatment [2].

In the five months leading up to admission at JH, the patient's parents sought multiple medical opinions that undoubtedly incurred significant financial and emotional stress. Countless other families and patients are unable to seek such extensive medical care due to socioeconomic barriers and geographic location. Thus, it is imperative to establish clear guidelines for diagnosis of rickets and subsequent workup for assessing underlying etiology.

CONCLUSION

Nephropathic cystinosis is a complex illness that has the potential of impacting multiple organ systems that can result in significant morbidity and mortality. In cases of rickets where malnutrition as an etiology is not clearly identified, further assessment for total renal wasting and cystinosis can aid in prompt treatment and replenishment of nutrient deficiencies. This case not only highlights the sequelae of undiagnosed NC but also the arduous and protracted journey a patient may experience when seeking a diagnosis and treatment.

REFERENCES

1. Prentice A. Nutritional rickets around the world. *J Steroid Biochem Mol Biol* 2013;136:201–6.
2. Nutritional rickets: A review of disease burden, causes, diagnosis, prevention and treatment. World Health Organization. 2019. [Available at: <https://www.who.int/publications/i/item/9789241516587>]
3. Klootwijk ED, Reichold M, Unwin RJ, Kleta R, Warth R, Bockenhauer D. Renal Fanconi syndrome: Taking a proximal look at the nephron. *Nephrol Dial Transplant* 2015;30(9):1456–60.
4. Nesterova G, Gahl WA. Cystinosis. 2001. In: Adam MP, Ardinger HH, Pagon RA, Wallace SE, Bean LJH, Stephens K, Amemiya A, editors. *GeneReviews*®. Seattle (WA): University of Washington, Seattle; 1993–2020.
5. Bertholet-Thomas A, Berthiller J, Tasic V, et al. Worldwide view of nephropathic cystinosis: Results from a survey from 30 countries. *BMC Nephrol* 2017;18(1):210.
6. Cherqui S, Courtoy PJ. The renal Fanconi syndrome in cystinosis: Pathogenic insights and therapeutic perspectives. *Nat Rev Nephrol* 2017;13(2):115–31.
7. Gahl WA, Balog JZ, Kleta R. Nephropathic cystinosis in adults: Natural history and effects of oral cysteamine therapy. *Ann Intern Med* 2007;147(4):242–50.

Acknowledgments

We would like to acknowledge and thank Dr. Issa Al Khtataba, senior consultant and pediatric nephrologist at Jordan Hospital in Amman, Jordan.

Author Contributions

Maryam Khan – Conception of the work, Design of the work, Acquisition of data, Analysis of data, Interpretation of data, Drafting the work, Revising the work critically for important intellectual content, Final approval of the version to be published, Agree to be accountable for all aspects of the work in ensuring that questions related to the accuracy or integrity of any part of the work are appropriately investigated and resolved

Patricia Beach – Conception of the work, Design of the work, Acquisition of data, Analysis of data, Interpretation

of data, Drafting the work, Revising the work critically for important intellectual content, Final approval of the version to be published, Agree to be accountable for all aspects of the work in ensuring that questions related to the accuracy or integrity of any part of the work are appropriately investigated and resolved

Sarah Hussein – Conception of the work, Design of the work, Acquisition of data, Analysis of data, Interpretation of data, Drafting the work, Revising the work critically for important intellectual content, Final approval of the version to be published, Agree to be accountable for all aspects of the work in ensuring that questions related to the accuracy or integrity of any part of the work are appropriately investigated and resolved

Mariam Jabr – Conception of the work, Design of the work, Acquisition of data, Analysis of data, Interpretation of data, Drafting the work, Revising the work critically for important intellectual content, Final approval of the version to be published, Agree to be accountable for all aspects of the work in ensuring that questions related to the accuracy or integrity of any part of the work are appropriately investigated and resolved

Jarir Halazun – Conception of the work, Design of the work, Acquisition of data, Analysis of data, Interpretation of data, Drafting the work, Revising the work critically for important intellectual content, Final approval of the version to be published, Agree to be accountable for all aspects of the work in ensuring that questions related to the accuracy or integrity of any part of the work are appropriately investigated and resolved

Hani Serag – Conception of the work, Design of the work, Acquisition of data, Analysis of data, Interpretation of data, Drafting the work, Revising the work critically for important intellectual content, Final approval of the version to be published, Agree to be accountable for all aspects of the work in ensuring that questions related to the accuracy or integrity of any part of the work are appropriately investigated and resolved

Guarantor of Submission

The corresponding author is the guarantor of submission.

Source of Support

None.

Consent Statement

Written informed consent was obtained from the patient for publication of this article.

Conflict of Interest

Authors declare no conflict of interest.

Data Availability

All relevant data are within the paper and its Supporting Information files.

Copyright

© 2020 Maryam Khan et al. This article is distributed under the terms of Creative Commons Attribution License which permits unrestricted use, distribution

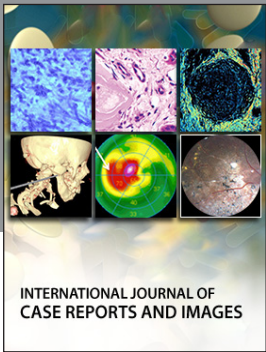
and reproduction in any medium provided the original author(s) and original publisher are properly credited. Please see the copyright policy on the journal website for more information.

Access full text article on
other devices



Access PDF of article on
other devices





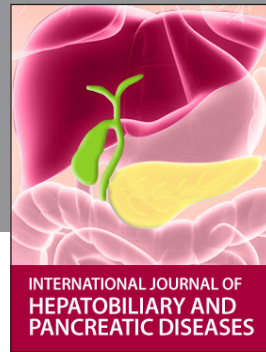INTERNATIONAL JOURNAL OF CASE REPORTS AND IMAGES



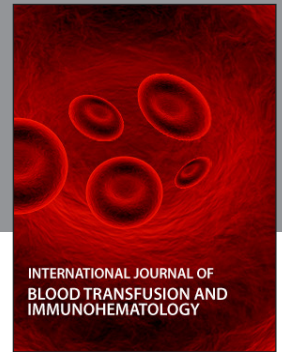VIDEO JOURNAL OF CLINICAL RESEARCH



VIDEO JOURNAL OF BIOMEDICAL SCIENCE




INTERNATIONAL JOURNAL OF HEPATOBILIARY AND PANCREATIC DISEASES



INTERNATIONAL JOURNAL OF BLOOD TRANSFUSION AND IMMUNOHEMATOLOGY



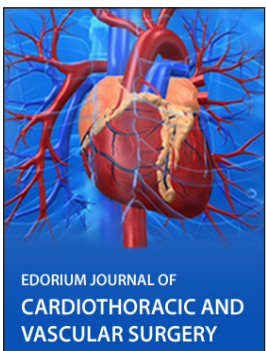
EDORIUM JOURNAL OF OPHTHALMOLOGY



Submit your manuscripts at
www.edoriumjournals.com



EDORIUM JOURNAL OF MEDICINE



EDORIUM JOURNAL OF CARDIOTHORACIC AND VASCULAR SURGERY



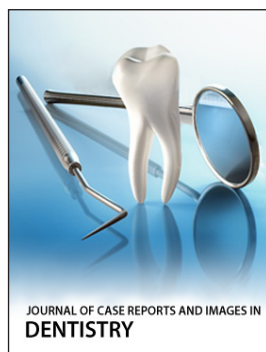
JOURNAL OF CASE REPORTS AND IMAGES IN ORTHOPEDICS AND RHEUMATOLOGY



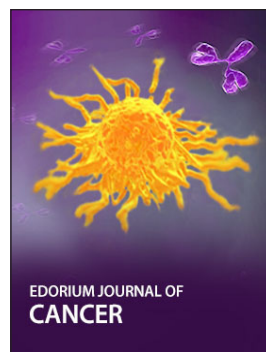EDORIUM JOURNAL OF PSYCHOLOGY




EDORIUM JOURNAL OF CELL BIOLOGY



JOURNAL OF CASE REPORTS AND IMAGES IN DENTISTRY



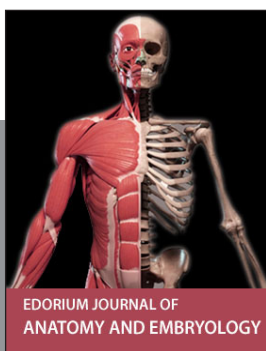EDORIUM JOURNAL OF CANCER



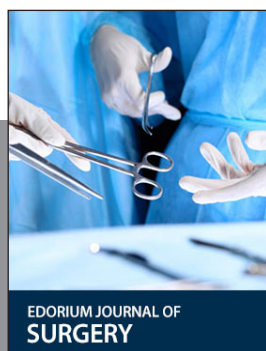EDORIUM JOURNAL OF PSYCHIATRY



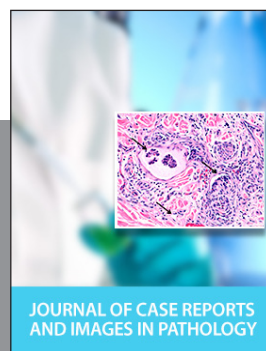JOURNAL OF CASE REPORTS AND IMAGES IN INFECTIOUS DISEASES



EDORIUM JOURNAL OF ANATOMY AND EMBRYOLOGY



EDORIUM JOURNAL OF SURGERY



JOURNAL OF CASE REPORTS AND IMAGES IN PATHOLOGY



EDORIUM JOURNAL OF ANESTHESIA