

Physiological striae atrophicae of adolescence

Shahid Ahmad, Khalid Latif Khan, Mehr Un Nisa

ABSTRACT

We report a 14-year-old adolescent boy, presenting with multiple horizontal linear striae on the back. There was no significant past medical illness and he was not taking any medications. Physiological striae atrophicae of adolescence are benign skin lesions. They commonly appear in adolescence due to a growth spurt. The common sites of presentation are the lower back and buttocks area. However, our case only had lesions on the back. The striae usually resolve with time and only need reassurance. Unfamiliarity of this condition can lead to suspicion of child abuse. The key is to readily recognize it and offer optimal reassurance. Topical treatment and laser therapy have been used to treat the lesions with varying degree of success.

Keywords: Adolescence, Physiological, Striae

How to cite this article

Ahmad S, Khan KL, Nisa MU. Physiological striae atrophicae of adolescence. J Case Rep Images Pediatr 2020;2:100006Z19SA2020.

Article ID: 100006Z19SA2020

doi: 10.5348/100006Z19SA2020CR

Shahid Ahmad¹, Khalid Latif Khan¹, Mehr Un Nisa¹

Affiliation: ¹Primary Health Care Corporation, Doha, Qatar.

Corresponding Author: Khalid Latif Khan, Villa 4, Street 611, Building 2 Zone 43, Doha, Qatar; Email: kkh@phcc.gov.qa

Received: 20 February 2020

Accepted: 25 March 2020

Published: 23 April 2020

INTRODUCTION

Physiological striae atrophicae of adolescence are associated with growth spurt in the teenage years. They usually present as multiple, horizontal, linear purplish, or white striae. They were first reported back in 1935 [1]. These striae do not have any identifiable underlying cause. The condition is more common in boys. The onset of striae is usually between 14 and 20 years of age in males and 10 and 16 years of age in females [1].

CASE REPORT

We report a 14-year-old boy presenting to the family medicine clinic with a history of striae on his back for the last four months (Figure 1). The striae were noticed incidentally, there was no history of pain, itching, physical exertion, or injury. There were no striae elsewhere on the body. The boy was thin and tall. No personal or family history of joint problems or connective tissue disorders was reported. The patient was not on any medications. On examination, the height of the boy was 176 cm and weight was 52 kg. Subsequent follow-up showed resolution of the striae with some residual scarring (Figure 2).

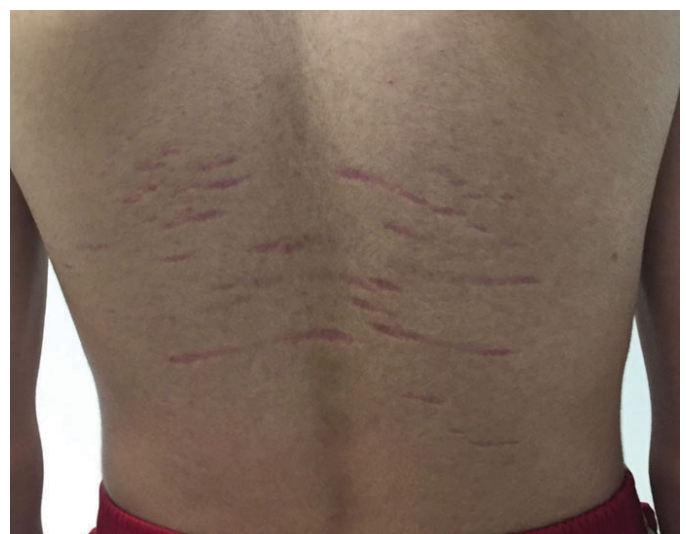

Figure 1: Linear purplish scar on the back of the teenager due to physiological phenomenon.

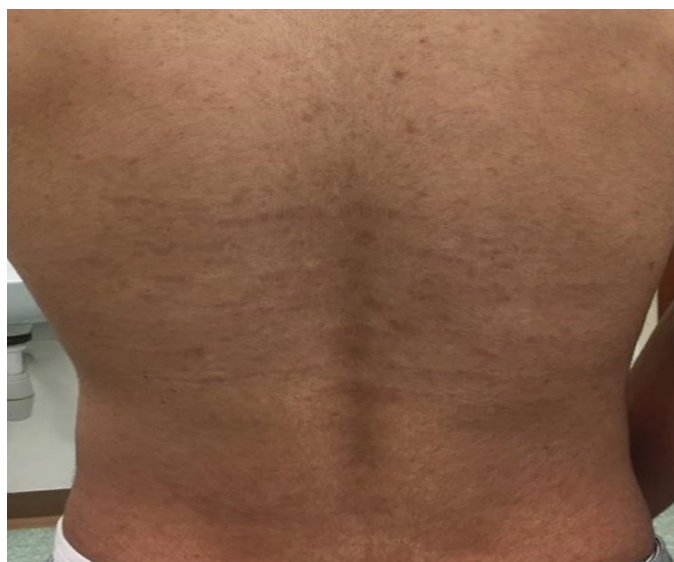

Figure 2: Resolution of the physiological striae with residual scarring.

DISCUSSION

Physiological striae atrophicae of adolescence usually occur during the growth spurt. They are common in boys than girls [1]. They typically present as red or purple, horizontal, linear streaks (striae rubra) in the lumbar area [2]. Over time, the color fades and the lesions become atrophic and silvery (striae alba). They are usually several centimeters long and 1–10 mm wide, with the long axis perpendicular to the direction of skin tension [3]. They are also reported to appear in unusual sites such as axilla, upper arms [4], and upper back [1]. Previously they have been grouped together with other similar linear lesions like striae distensae [5, 6]. Striae distensae or stretch marks mainly result from distention of skin commonly seen in pregnant women (striae gravidarum), Cushing's syndrome, Marfan's syndrome, obesity, and corticosteroid use [5, 6]. Striae distensae are more common in girls and are more common at sites which are associated with distention, such as lower abdomen, breast, and thighs [1, 6].

In contrast, it is believed now that only distention of the skin is not the reason for the striae of adolescents, but genetic and hormonal factors play a part as well. They can appear in healthy and nonobese adolescents [1, 4].

It is important to distinguish these striae from the striae caused by other diseases. Cushing disease, Marfan's syndrome, Ehlers–Danlos syndrome, and complication of corticosteroid treatment are common differential diagnosis in this age group [7]. Linear focal elastosis is another dermatological presentation which looks similar; however, they are yellow palpable linear marks on the back and more common in older age [1, 4]. Various treatments such as topical tretinoin and laser treatment have been tried with variable results but any cure for the

lesions have not been found yet [4, 5]. The presentation of the striae in teenagers, without any obvious cause, has also resulted in suspicion of non-accidental injury and this has widely been reported in the literature [1, 8, 9].

CONCLUSION

The physiological striae atrophicae of adolescence possibly are totally distinct entities than other striae, such as striae distensae. The most important aspect of their management is prompt diagnosis and reassurance to the patient/parents regarding the benign nature of the problem and its gradual resolution. Health care professionals dealing with children should be aware of this condition, so it could be distinguished from non-accidental injuries and unnecessary referral to social services and false accusation of child abuse could be avoided.

REFERENCES

1. Leung AK, Barankin B. Physiological striae atrophicae of adolescence with involvement of the upper back. *Case Rep Pediatr* 2013;2013:386094.
2. Mishriki YY. Asymptomatic 'streaks' in a healthy young man. *Adolescence lumbar striae*. *Postgrad Med* 2000;107(4):237–40.
3. Burk CJ, Pandrangi B, Connelly EA. Picture of the month. Striae. *Arch Pediatr Adolesc Med* 2008; 162(3):277–8.
4. Leung AKC, Barankin B. Physiological striae atrophicae of adolescence with involvement of the axillae and proximal arms. *Case Rep Pediatr* 2017;2017:7678086.
5. Ditre CM, Whitney K. Striae distensae (striae atrophicae). *Dermatology Advisor* 2013.
6. Al-Himdani S, Ud-Din S, Gilmore S, Bayat A. Striae distensae: A comprehensive review and evidence-based evaluation of prophylaxis and treatment. *Br J Dermatol* 2014;170(3):527–47.
7. Fischer G. Linear lesions on a teenager's back. *Medicine Today* 2017.
8. Elshimy N, Gandhi A. A teenager with lumbar striae distensae (when a bruise is not a bruise). *BMJ Case Rep* 2013;2013. pii:bcr2013201962.
9. Cohen HA, Matalon A, Mezger A, Ben Amitai D, Barzilai A. Striae in adolescents mistaken for physical abuse. *J Fam Pract* 1997;45(1):84–5.

Acknowledgments

We thank and acknowledge Dr. Mansoor Hameed's kind contribution toward publishing of this article.

Author Contributions

Shahid Ahmad – Conception of the work, Acquisition of data, Analysis of data, Interpretation of data, Drafting the

work, Final approval of the version to be published, Agree to be accountable for all aspects of the work in ensuring that questions related to the accuracy or integrity of any part of the work are appropriately investigated and resolved

Khalid Latif Khan – Conception of the work, Acquisition of data, Drafting the work, Final approval of the version to be published, Agree to be accountable for all aspects of the work in ensuring that questions related to the accuracy or integrity of any part of the work are appropriately investigated and resolved

Mehr Un Nisa – Design of the work, Analysis of data, Revising the work critically for important intellectual content, Final approval of the version to be published, Agree to be accountable for all aspects of the work in ensuring that questions related to the accuracy or integrity of any part of the work are appropriately investigated and resolved

Guarantor of Submission

The corresponding author is the guarantor of submission.

Source of Support

None.

Consent Statement

Written informed consent was obtained from the patient for publication of this article.

Conflict of Interest

Authors declare no conflict of interest.

Data Availability

All relevant data are within the paper and its Supporting Information files.

Copyright

© 2020 Shahid Ahmad et al. This article is distributed under the terms of Creative Commons Attribution License which permits unrestricted use, distribution and reproduction in any medium provided the original author(s) and original publisher are properly credited. Please see the copyright policy on the journal website for more information.

Access full text article on
other devices



Access PDF of article on
other devices





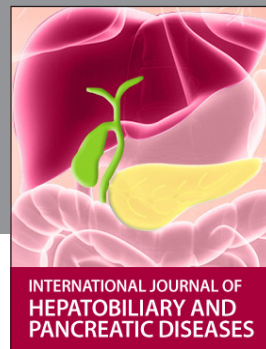INTERNATIONAL JOURNAL OF CASE REPORTS AND IMAGES



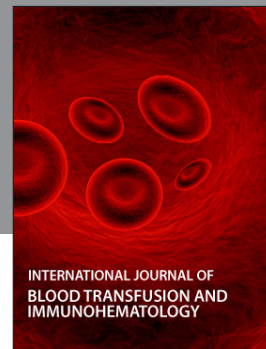VIDEO JOURNAL OF CLINICAL RESEARCH



VIDEO JOURNAL OF BIOMEDICAL SCIENCE




INTERNATIONAL JOURNAL OF HEPATOBILIARY AND PANCREATIC DISEASES



INTERNATIONAL JOURNAL OF BLOOD TRANSFUSION AND IMMUNOHEMATOLOGY



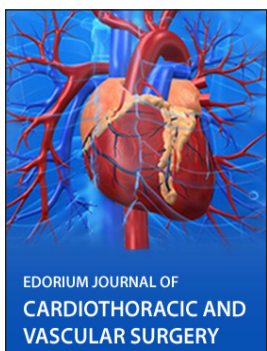EDORIUM JOURNAL OF OPHTHALMOLOGY



Submit your manuscripts at
www.edoriumjournals.com



EDORIUM JOURNAL OF MEDICINE



EDORIUM JOURNAL OF CARDIOTHORACIC AND VASCULAR SURGERY



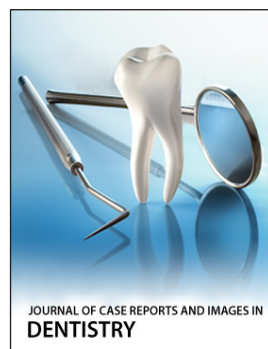
JOURNAL OF CASE REPORTS AND IMAGES IN ORTHOPEDICS AND RHEUMATOLOGY



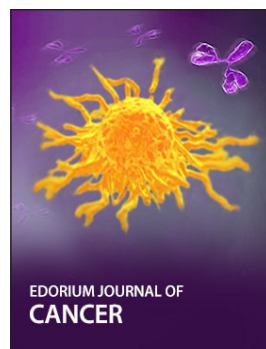EDORIUM JOURNAL OF PSYCHOLOGY




EDORIUM JOURNAL OF CELL BIOLOGY



JOURNAL OF CASE REPORTS AND IMAGES IN DENTISTRY



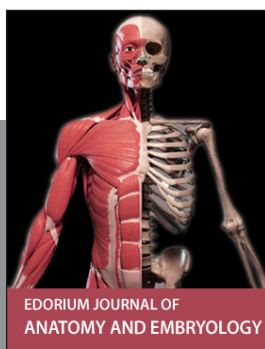EDORIUM JOURNAL OF CANCER



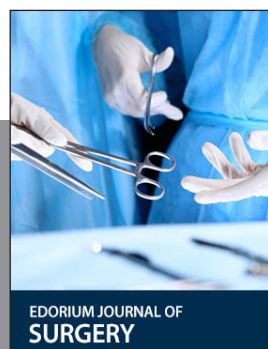EDORIUM JOURNAL OF PSYCHIATRY



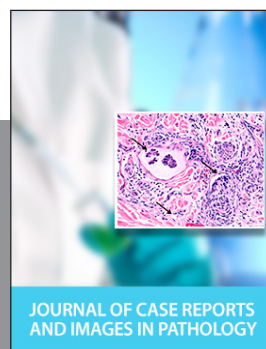JOURNAL OF CASE REPORTS AND IMAGES IN INFECTIOUS DISEASES



EDORIUM JOURNAL OF ANATOMY AND EMBRYOLOGY



EDORIUM JOURNAL OF SURGERY



JOURNAL OF CASE REPORTS AND IMAGES IN PATHOLOGY



EDORIUM JOURNAL OF ANESTHESIA