

Intramuscular lipoma of thigh

Smit Shah, Praful Shah

CASE REPORT

Patient is a 17-years-old obese male with a past medical history of well controlled Diabetes Mellitus who presented with progressive painless swelling in left thigh (Figure 1) since last six months. Patient reported that swelling was small initially, but it gradually increased in size. On physical examination, painless mass was noted that originated from Anterior Superior Iliac Spine (ASIS) and extended to lateral epicondyle of the left femur. Patient denied any weight loss, fever or other systemic symptoms. Lower extremity ultrasound was performed, and diagnosis of lipoma was confirmed (Figure 2). Lipoma excision was planned. Patient was placed under saddle anesthesia; long 12 cm vertical incision was made on the anterior aspect of left thigh and two well encapsulated masses were dissected in Figures 3(A and B). Specimen was sent for pathological evaluation and it confirmed two solitary lipomas which were yellowish, nodular with dull tan areas without any cellular atypia or abnormal infiltration and measured 16x11x8 cm and 16x15x8 cm respectively. Jackson Pratt (JP) drain was placed (Figure 4) which was removed after ten days. Wound care was suggested and sutures were removed after three weeks. The patient did not have any post operative deficits and was stable after removal of JP drain and suture removal. Post operatively patient was normal without any motor or sensory anomalies in the left lower extremity. Patient was also recommended to follow up with physical and occupational therapy for quick recovery.

Smit Shah¹, Praful Shah²

Affiliations: ¹Medical Student, Rutgers Robert Wood Johnson Medical School, Piscataway, New Jersey, 08854, USA; ²MS General Surgeon, Fellow of Minimal Access Surgery, India.

Corresponding Author: Smit Shah, 112 Montgomery Street, Apt 3G, Highland Park, New Jersey, USA, 08904; Email: spshah1991@gmail.com

Received: 13 January 2018

Accepted: 05 March 2018

Published: 22 March 2018

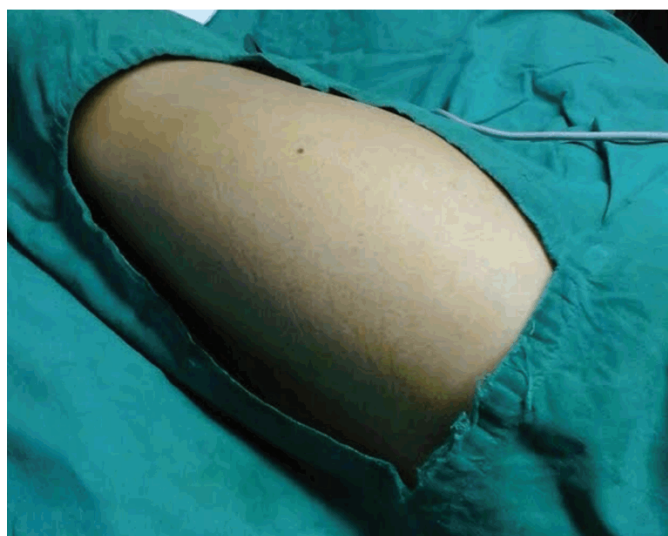

Figure 1: Protruding, mobile, painless mass seen in the left lower extremity (Left thigh) extending from ASIS to femoral epicondyle (Preoperative findings).

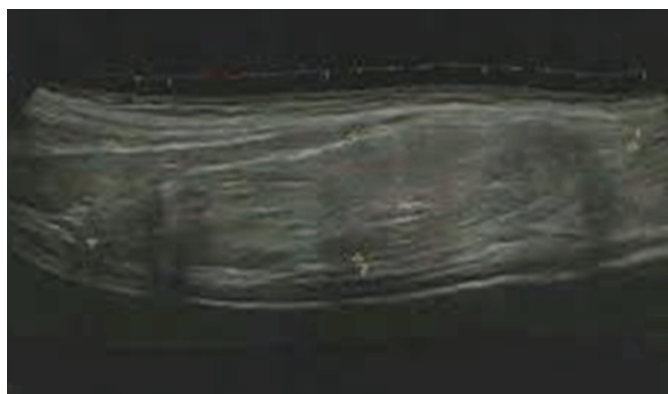


Figure 2: Avascular, homogeneous, hyper-echoic mass seen in the left lower extremity during Ultrasound examination. No evidence of calcification or tissue necrosis.

DISCUSSION

Lipoma is benign soft tissue tumor that usually presents as slow growing, painless, well circumscribed mass varying in size in different parts of the body.

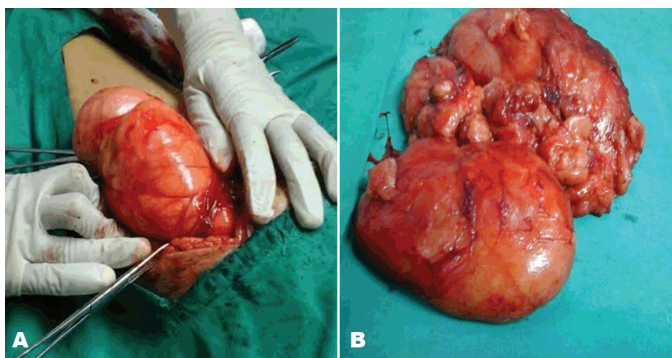


Figure 3(A and B): Intra-operative findings suggestive of two yellowish tan masses with different sizes demonstrating lipomas.

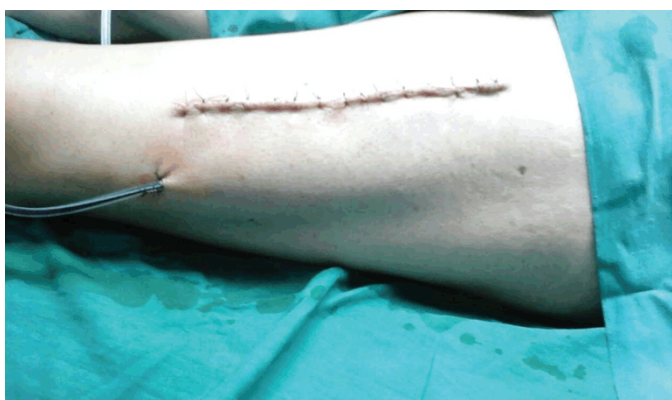

Figure 4: Post-Operative findings: Jackson Pratt (JP) drain that was removed after ten days.

Reported anatomical sites include joints, extra-dural with respect of spinal cord, breast, back and also other unusual locations like heart with or without septal involvement [1, 2, 3]. Numerous etiologies have been proposed for Lipoma. For instance, based on studies by Schoenmakers E. et al., aberrant genetic rearrangements on human chromosome 12 known as HMG1C have been known to cause solid benign lipomatous tumors [4]. In addition, hereditary conditions like Familial Multiple Lipomatosis have been known to present with multiple painless masses on trunk and extremities sparing the forehead with higher incidence in males as compared to females [5]. Other disorders include Dercum's disease [6] and Madelung's disease [7] with former being more commonly associated with obesity in post menopausal women and latter being associated with alcohol consumption. Lipomas can be characterized in several different ways [2]. These include solitary lipomas which are isolated, benign and well circumscribed, angiomyolipomas which are tender subcutaneous masses which are somewhat firmer as opposed to the rubbery consistency and congenital diffuse lipomas which are composed of immature fat cells that occur on trunk and back. In addition, if lipomas are larger than ten cm, liposarcoma needs to be ruled out by ensuring lack of associated symptoms like weight loss [8].

In this case, we demonstrate a patient with an Intramuscular lipoma in the left lower extremity originating from ASIS, extending onto lateral epicondyle of the femur. It was interesting to see that despite such a huge size, patient did not have any sensory or vascular symptoms due to compression of neuro-vasculature located in that area. From a surgical stand point, during lipoma excision, care must be taken to ensure that muscle fibers and attachments are spared in order to prevent motor problems related to knee extension and hip flexion. Specifically injury to rectus femoris and vastus muscles is very common during cauterization which may cause muscular fibrosis that can present with motor symptoms post operatively. In addition, patient must be monitored for compartment syndrome secondary to tight facial closure.

CONCLUSION

In summary, we have presented a case of a patient with a benign intramuscular lipoma that was successfully diagnosed and treated with surgical removal and excellent post-operative recovery.

Keywords: Diabetes Mellitus, Intramuscular, Jackson Pratt (JP) drain, Lipoma

How to cite this article

Shah S, Shah P. Intramuscular lipoma of thigh. J Case Rep Images Pediatr 2018;1:100001Z19SS2018.

Article ID: 100001Z19SS2018

doi:10.5348/100001Z19SS2018CL

REFERENCES

1. Fang L, He L, Chen Y, Xie M, Wang J. Infiltrating lipoma of the right ventricle involving the interventricular septum and tricuspid Valve: Report of a rare case and literature review. *Medicine (Baltimore)* 2016 Jan;95(3):e2561.
2. Kamaci S, Doral MN, Ergen FB, Yucekul A, Cil A. Lipoma arborescens of the knee. *Knee Surg Sports Traumatol Arthrosc* 2015 Aug;23(8):2196–201.
3. Loriaux DB, Adogwa O, Gottfried ON. Radiculopathy in the setting of lumbar nerve root compression due to an extradural intraforaminal lipoma: A report of 3 cases. *J Neurosurg Spine* 2015 Jul;23(1):55–8.

4. Schoenmakers EF, Wanschura S, Mols R, Bullerdiek J, Van den Berghe H, Van de Ven WJ. Recurrent rearrangements in the high mobility group protein gene, HMGI-C, in benign mesenchymal tumours. *Nat Genet* 1995 Aug;10(4):436–44.
5. Toy BR. Familial multiple lipomatosis. *Dermatology Online Journal* 2003;9(4).
6. Hansson E, Svensson H, Brorson H. Review of Dercum’s disease and proposal of diagnostic criteria, diagnostic methods, classification and management. *Orphanet J Rare Dis* 2012 Apr 30;7:23.
7. Nisi G, Sisti A. Images in clinical medicine: Madelung’s Disease. *N Engl J Med* 2016 Feb 11;374(6):572.
<http://www.lipoma.net/category/types-of-lipoma-tumors>

important intellectual content, Final approval of the version to be published
 Praful Shah – Substantial contributions to conception and design, Acquisition of data, Analysis and interpretation of data, Drafting the article, Revising it critically for important intellectual content, Final approval of the version to be published

Guarantor of Submission

The corresponding author is the guarantor of submission.

Source of Support

None

Consent Statement

Written informed consent was obtained from the patient for publication of this study.

Conflict of Interest

Authors declare no conflict of interest.

Copyright

© 2018 Smit Shah et al. This article is distributed under the terms of Creative Commons Attribution License which permits unrestricted use, distribution and reproduction in any medium provided the original author(s) and original publisher are properly credited. Please see the copyright policy on the journal website for more information.

SUGGESTED READING

- <https://emedicine.medscape.com/article/191233-overview>
- <https://www.uptodate.com/contents/search?search=Lipoma>

Author Contributions

Smit Shah – Substantial contributions to conception and design, Acquisition of data, Analysis and interpretation of data, Drafting the article, Revising it critically for

Access full text article on other devices



Access PDF of article on other devices

